



RESEARCH ARTICLE

BILATERAL DENTIGEROUS CYST- A RARE CASE REPORT

¹Dr. Shruthi, R., ^{2,*}Dr. Priyanka. R. Bhooboo and ³Dr. Ranjeeta Yumnam

¹Professor, Dept of Oral and Maxillofacial Surgery, Institution, Rajarajeswari Dental College, Bangalore, India

^{2,3}Post Graduate in Dept of Oral and Maxillofacial Surgery, Institution, Rajarajeswari Dental College, Bangalore

ARTICLE INFO

Article History:

Received 04th March, 2017

Received in revised form

24th April, 2017

Accepted 16th May, 2017

Published online 30th June, 2017

ABSTRACT

Dentigerous cysts are the most common developmental cysts of the jaw, most frequently associated with impacted mandibular third molar teeth. Bilateral dentigerous cysts are rare and occur typically in association with a developmental syndrome. The reported occurrence of bilateral dentigerous cyst in the absence of a syndrome is rare. Here we report a case of bilateral nonsyndromic, dentigerous cyst in mandible of non-syndromic 15year old female patient.

Key Words:

Bilateral dentigerous cyst,
Non-syndromic,
Enucleation,
Mandible,
Third molar.

Copyright©2017, Shruthi et al. This is an open access article distributed under the Creative Commons Attribution License, which permits unrestricted use, distribution, and reproduction in any medium, provided the original work is properly cited.

Citation: Dr. Shruthi, R., 2Dr. Priyanka. R. Bhooboo and Dr. Ranjeeta Yumnam. 2017. "Bilateral dentigerous cyst- a rare case report", *International Journal of Development Research*, 7, (06), 13400-13403.

INTRODUCTION

A dentigerous cyst is an epithelial-lined developmental cavity that encloses the crown of an unerupted tooth at the cemento-enamel junction (Daley, 1994). After radicular cysts, dentigerous cysts are second most commonly diagnosed, accounting for 24% of all jaw cysts. They are often asymptomatic and are diagnosed incidentally during routine examination (Morais, 2014). Their frequency in general population has been estimated at 1.44 cyst for every 100 unerupted teeth (Mourshed, 1964). Although dentigerous cysts are highly prevalent, bilateral occurrence is rare and usually associated with syndromes or systemic diseases (Freitas *et al.*, 2006), such as Maroteaux-Lamy syndrome (Ko, 1999), cleidocranial dysplasia and mucopolysaccharidosis. In absence of these syndromes bilateral dentigerous cyst are rare. We report a case of non-syndromic bilateral dentigerous cyst in a 15year old patient involving impacted mandibular third molars.

CASE REPORT

A patient reported to the clinic complaining of discharge of pus from right side cheek (Figure 1). Patient gives history of swelling since one week which was insidious in onset, small in size and gradually increased. Area was not painful initially but she later developed dull continuous pain. Discharge of thick creamy yellow colour fluid was observed since two days which increases on applying pressure. Medical history was non contributory. On examination diffuse swelling was observed on right cheek region measuring 3×3cms, with pus draining extra oral sinus. The swelling was soft in consistency, non tender and surrounding area appeared normal. Extraoral sinus had necrotic tissue around and discharge was increasing on pressure and foul smelt. Intraorally impacted third molar tooth crown was observed on right side, pericoronal flap was normal (Figure 2). Deep pocket was evident distal to right mandibular second molar. The vestibule and surrounding tissue were appearing normal and were nontender on palpation. On aspiration frank pus was obtained. Orthopantomogram showed well defined radiolucency in mandible with impacted tooth bilaterally (Figure 3). On the right side was horizontally impacted third molar with unilocular radiolucency measuring 2.5×3cms with sclerotic margin extending from distal aspect of

*Corresponding author: Dr. Priyanka, R.,

Post Graduate in Dept of Oral and Maxillofacial Surgery, Institution, Rajarajeswari Dental College, Bangalore.

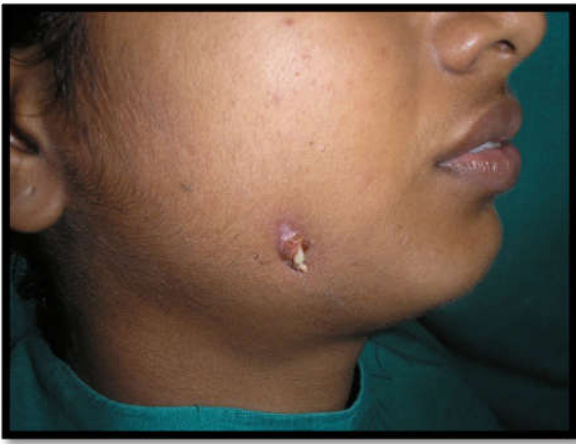

Figure 1. Extraoral view showing pus draining from fistula in lower right cheek region

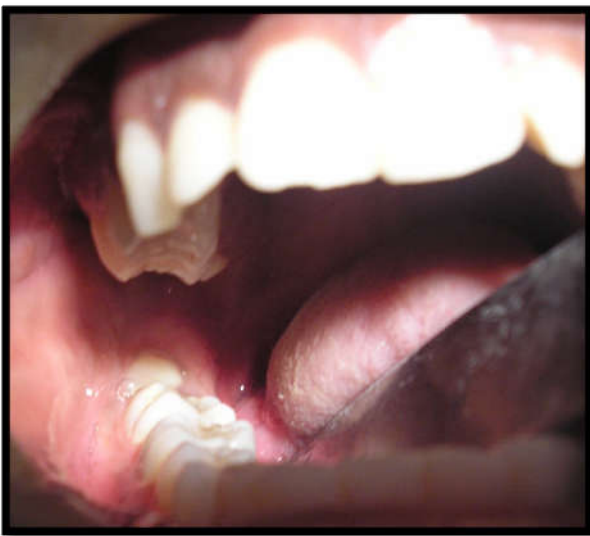

Figure 1: Intraoral view showing swelling in the lower right quadrant.

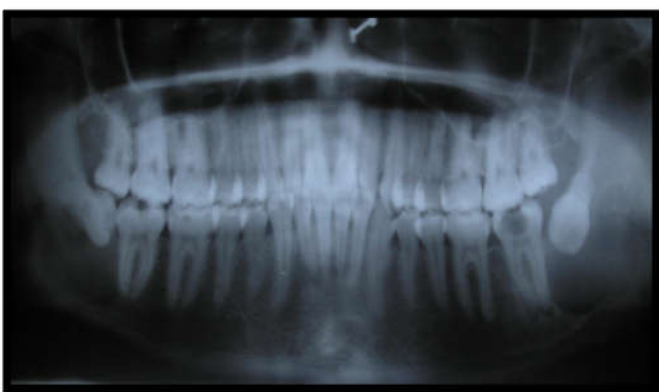

Figure 2: Orthopantomogram showing bilateral radiolucency in the lower jaw around impacted 38 and 48 teeth.

second molar 3cms posteriorly and from impacted tooth lower border leaving 5mm of bone inferiorly (Figure 4a). Inferior alveolar canal seemed to be involved in the lesion. On left side radiolucency measuring 3×3cms with floating third molar and involving the lower border and pushing the canal inferiorly (Figure 4b). Both lesions were provisionally diagnosed as dentigerous cyst and biopsy was done on both sides with gap of three days.

Histopathologic slides of right side lesion showed connective tissue wall lined by odontogenic epithelium of variable thickness (Figure 5a). The connective tissue wall is composed of loose fibrous connective tissue with inflammatory infiltrate. The left side lesion slide showed odontogenic epithelial lining with reduced enamel epithelium like cells with connective tissue walls showing odontogenic ectomesenchyme with dystrophic calcification (Figure 5b). The overall features were diagnostic of dentigerous cyst. Surgical enucleation of the cysts was carried out under general anesthesia. The involved impacted third molars were removed in toto with cystic lining. Additional grossly carious 37 tooth was extracted. The surgical specimens were sent for final diagnosis which was confirmed to be a dentigerous cyst.

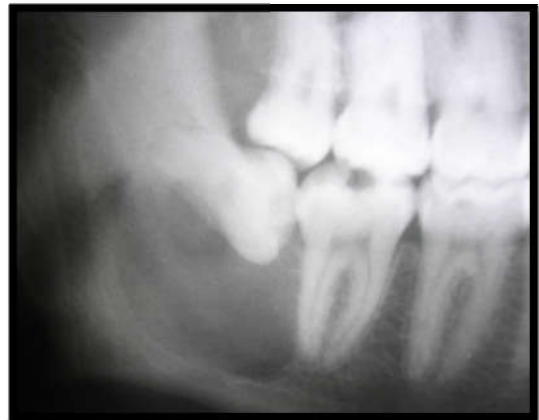

Figure 3 a: OPG showing radiolucency in the lower right quadrant.

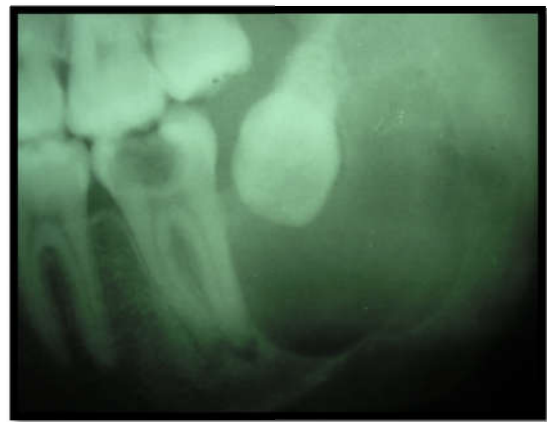


Figure 4 b: OPG showing radiolucency in the lower left quadrant.

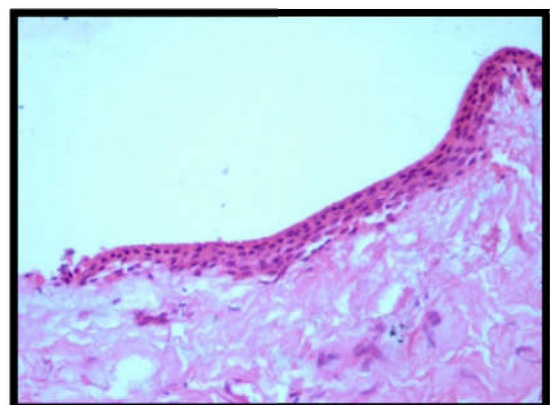


Figure 5a: Histopathologic slide showing evidence of a dentigerous cyst.

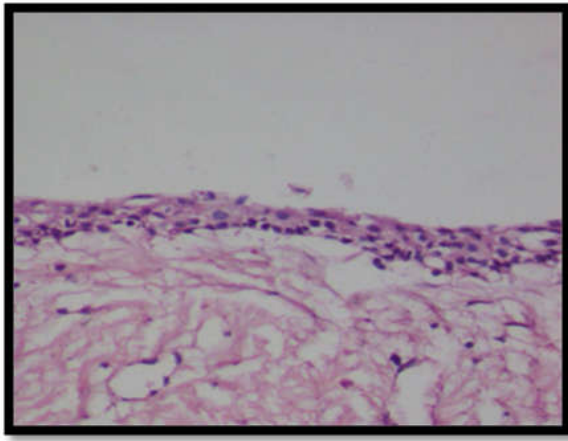


Figure 6b: Histopathologic slide Picture of left side lesion showing evidence of dentigerous cyst.

DISCUSSION

Dentigerous cyst usually occur in 2nd and 3rd decade of life (Shear, 2007). It can originate from any tooth, including supernumerary teeth (Som, 1992), with incidence being 45.7% involving third molars were as in maxillary premolars it is 2.7%⁶. These lesions are asymptomatic and are usually found in children and adolescent with a male predilection (Shafer, 2007; Cawsons *et al.*, 2008). In the present case it was a 15 year old female patient with chief complaint of swelling and pus discharge from the cheek. Toller has stated that the likely origin of dentigerous cyst is breakdown of proliferating cells of the follicle after impeded eruption. These breakdown products result in increased osmotic pressure resulting in cyst formation (Tamgadge *et al.*, 2011). Although dentigerous cysts are common developmental cyst, bilateral cysts are rare and usually associated with syndromes like cleidocranial dysplasia, basal cell nevus syndrome (Ustuner *et al.*, 2003). Only 21 reported cases of bilateral dentigerous cyst without underlying syndromes or systemic disease (Tamgadge *et al.*, 2011). Pleomorphism in chromosome 1qh+ has been reported with this condition (Batra *et al.*, 2004). It is suggested to do karyotyping in non-syndromic patient to confirm association with chromosome 1anomaly or its relation with other chromosomes. The combined effect of cyclosporine and calcium channel blocker is reported to be a cause bilateral dentigerous cyst. In the present case, the patient had no underlying syndrome or systemic disease.

Since the cyst can attain large size with minimum or no symptoms, early detection and removal of cyst is important to reduce morbidity. It is therefore important to perform radiographic examination of unerupted teeth (Ko, 1999). An orthopantomogram gives a better view of all the erupted and unerupted teeth with their associated lesions⁵. Radiographically dentigerous cyst appears as a well circumscribed, unilocular, symmetric radiolucency around the crown of impacted tooth. The differential diagnosis of dentigerous cyst must include primordial cyst, keratocyst, odontogenic tumors like unilocular ameloblastoma, adenomatoid odontogenic tumor, ameloblastic fibroma^{14,15}. These were ruled out after the biopsy result revealed it to be dentigerous cyst. Treatment of dentigerous cyst usually consist of enucleation. But in cases of larger cyst marsupialization is indicated (Morais *et al.*, 2014).

In majority of cases enucleation and extraction is performed via intraoral approach. But there are reports in which extraoral Risdon's approach being used (Ellis, 2006; Mintz, 2001). Conservative approach has also been used by some authors as a mode of treatment for dentigerous cyst by decompression which lead to spontaneous regression (Chew, 2008; Shah *et al.*, 2002). In the case described herein, enucleation for both the cyst was performed intraorally under general anesthesia.

REFERENCES

- Daley TD, Pringle GA. 1994. Relative incidence of odontogenic tumors and oral and jaw cysts in a Canadian population. *Oral Sur Oral Med Oral Pathol*, 77:276-80.
- Morais H *et al.* 2014. Bilateral mandibular dentigerous cysts: a case report. *RGO, Rev Gaúch Odontol, Porto Alegre*, v.62, n.3, p. 299-304.
- Mourshed F. 1964. A roentgenographic study of dentigerous cysts. Incidence in a population sample. *Oral Surg Oral Med Oral Pathol*, 18:47-53.
- Freitas DQ, Tempest LM, Sicolis E and Lopes-Neto FC. 2006. Bilateral dentigerous cysts: review of the literature and report of an unusual case. *Dentomaxillofac Radiol*, 35(6):464-8.
- Ko KS, Dover DG, Jordan RC. 1999. Bilateral dentigerous cysts—report of an unusual case and review of the literature. *J Can Dent Assoc.*;65(1):49-51.
- Shear M, Speight PM. 2007. *Cyst of oral and maxillofacial regions*. 4th ed. New Jersey: Blackwell publishers; p. 59-75.
- Som PM, Shangold LM, Biller HF. 1992. A palatal dentigerous cyst arising from a mesiodente. *Am H Neuroradiol*; 13(1):212-4.
- Shafer H, Levy. 2007 *Cyst and tumors of odontogenic origin in Shafer's textbook of oral pathology*. 5th ed. New Delhi: Elsevier India; p. 358-61.
- Cawsons RA, Odell EW. *Cowson's essentials of oral pathology and medicine*. 8th ed. Philadelphia: Churchill livingstone, Elsevier. p. 108-9.
- Tamgadge A, Tamgadge S, Bhatt D. 2011. Bilateral dentigerous cyst in a non-syndromic patient: Report of an unusual case with review of the literature. *J Oral Maxillofac Pathol*. Jan-Apr; 15(1): 91-95.
- Ustuner E, Fitoz S, Atosoy C. 2003. Bilateral dentigerous cysts in impacted maxillary cuspids in non syndromic patient. *Oral Surg Oral Med Oral Pathol*; 95:632-5.
- Batra P, Roychoudhury A, Balakrishnan P, Parkash H. (2004). Bilateral dentigerous cyst associated with polymorphism in chromosome 1qh+. *J Clin Pediatr Dent*; 28:177-81.
- Yamalik K, Bozkaya S, Erkmén E. 2007. Nonsyndromic bilateral mandibular dentigerous cysts: report of a rare case. *Turkiye Klinikleri J Dent Sci*; 13:129-33.
- Aziz SR, Pulse C, Dourmas MA, Roser SM. 2002. Inferior alveolar nerve paresthesia associated with a mandibular dentigerous cyst. *J Oral Maxillofac Surg*. 60(4):457-9. doi: 10.1053/joms.2002.31238.
- Martinez-Perez D, Varela-Morales M. 2001 Conservative treatment of dentigerous cysts in children: a report of 4 cases. *J Oral Maxillofac Surg*. 59(3):331-3. doi: 10.1053/joms.2001.21006.
- Morais HHA, SouzaDias TG, Vasconcellos RJ. 2014. Bilateral mandibular dentigerous cysts: a case report *RGO, Rev Gaúch Odontol, Porto Alegre*, v.62, n.3, p. 299-304, out./dez.

- Ellis E, Zide MF. 2006. Surgical approaches to the facial skeleton. 2 ed. Baltimore: Williams & Wilkins.
- Mintz S, Allard M, Nour R. 2001. Extraoral removal of mandibular odontogenic dentigerous cysts: a report of 2 cases. *J Oral Maxillofac Surg.* 59(9):1094-6. doi: 10.1053/joms.2001.25857.
- Chew YS, Aghabeigi B. 2008. Spontaneous regression of bilateral dentigerous cysts: a case report. *Dent Update.* 35(1):63-5.
- Shah N, Thuau H, Beale I. 2002. Spontaneous regression of bilateral dentigerous cysts associated with impacted mandibular third molars. *Br Dent J.* 192(2):75-6. doi:10.1038/sj.bdj.4801297.
