



Full Length Research Article

INNERVATION OF THE OLFACTORY APPARATUS OF *CHALCIDES SEPOIDES*  
(SQUAMATA- LACERTILIA- SCINCIDAE)

<sup>1,\*</sup> Amel Ramadan Omar and <sup>2</sup>Ahmed I. Dakrory

<sup>1</sup>Lecturer of Comparative anatomy & Embryology Cairo University, Faculty of Science, Department of Zoology  
<sup>2</sup>Department of Zoology, Faculty of Science, Cairo University, Egypt

ARTICLE INFO

Article History:

Received 14<sup>th</sup> December, 2015  
Received in revised form  
05<sup>th</sup> January, 2016  
Accepted 10<sup>th</sup> February, 2016  
Published online 31<sup>st</sup> March, 2016

Key Words:

*Chacidessepoides*,  
Olfactory apparatus,  
Nervi Terminalis and Vomeronasalis,  
Nervusolfactorius.

ABSTRACT

The aim of this study is to analyze the three nerves; terminalis, vomeronasalis and olfactorius emerging from the olfactory apparatus. The lizard *Chacidessepoides* was collected from Sinai and was undergone to permanent histological preparation. Through the examination of the olfactory apparatus of this species resulted in the vomeronasal organ is innervated by two correlating nerves: terminal and vomeronasal nerves that originating from its sensory epithelium. The terminal nerve bears the ganglion terminale. The olfactory nerve innervates the olfactory chamber. The three nerves leave the nasal capsule through the fenestra olfactoria advehens as separate bundles. They enter the cranial cavity through the fenestra olfactoriaevehens. The olfactory nerve connected with the main olfactory bulb. The terminal connects with the outer layer of the brain, while the vomeronasal one joins the accessory olfactory bulb. The three nerves are perispicuous special sensory.

Copyright © 2016, Amel Ramadan Omar and Ahmed I. Dakrory. This is an open access article distributed under the Creative Commons Attribution License, which permits unrestricted use, distribution, and reproduction in any medium, provided the original work is properly cited.

INTRODUCTION

The family Scincidae or the skinks are like true lizards (as families Agamidae and Chamaeleonidae) with their legs are relatively small. They are the most diverse families of lizards with more than 1500 known species (Mecke et al., 2013). Skinks are typically diurnal, terrestrial and active on the surface of the ground or low roosts, with some species are mountaineers, living in trees or on rocks and few others are semiaquatic and able to swim and hide under water to escape predators (Daniels and Heatwole, 1990). According to Disi et al. (2006) the scincid lizard *Chacidessepoides* or Wedge-snouted skink is found in sandy areas, dunes and sandy soil, and has been seen close to oases. It moves very efficiently by swimming in the sand below the surface. The same authors reported that this species is a viviparous, nocturnal in the summer and diurnal in the winter. In the reptiles in general and the lacertilian in particular, the olfactory apparatus is formed of two parts; the main olfactory organ and the accessory olfactory one (the vomeronasal or Jacobson's organ). With regard to the study of the cranial nerves of reptiles, many studies were carried out on both Lacertilia and Ophidia (Dakrory, 1994; El-Ghareeb et al., 2004; Abdel-Kader, 2006, Abdel-Kader et al., 2007; Omar et al., 2015).

The study of the anatomy and morphology of the cranial nerves among members of the family Scincidae is infrequent. Hence, it was important to study the anterior cranial nerves that innervate the sensory olfactory system of a member of this family to elucidate their neural characters and to analyze the fibre components of these nerves. This may help in understanding the phylogeny, of this primitive scincidian family.

MATERIALS AND METHODS

Habitat and Ecology

The species used in this study is *Chacidessepoides* (Family: Scincidae). It is a sand dwelling fossorial species with frequently reduced limbs for sand locomotion. This lizard is diurnal, feeding on insects, spread in a wide range of habitat from depressions of Western desert to the sand areas in the rock wadies of the eastern desert and Sinai.

Sample Preparation for permanent histological slides

Two specimens of the fully formed embryos of *Chacidessepoides* were collected from two pregnant females in the laboratory and forthwith fixed in aqueous Bouin's solution for a day.

\*Corresponding author: Amel R. Omar,  
Lecturer of Comparative anatomy & Embryology Cairo University,  
Department of Zoology, Faculty of Science

After fixation, the two embryos were transferred to decalcifying EDTA for about 30 to 50 days with changing the solution every four days. This will be followed by washing with distilled water and transferred in 70% ethyl alcohol for about two days. Then the heads will be treated with ascending series of ethyl alcohol and cleared in xylene followed by embedding in paraffin wax. Serial transverse sections were obtained using the microtome with thickness 10µm. The serial sections were then stained in Mallory's triple stain.

**Graphical Photomicrographs**

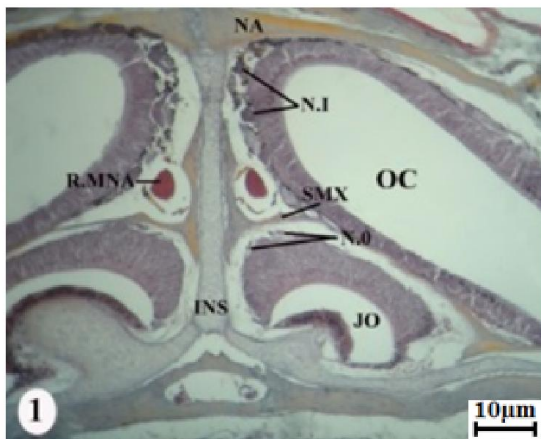
Photomicrographs for parts of the transverse sections were made to demonstrate the position and relations of the nerves to the other structures of the head.

**RESULTS**

The microscopic examination of the serial sections of *Chacidessepoides* revealed the presence of a nervus terminalis originates in combination with the vomeronasal nerve from the sensory epithelium of Jacobson's organ or the vomeronasal organ.

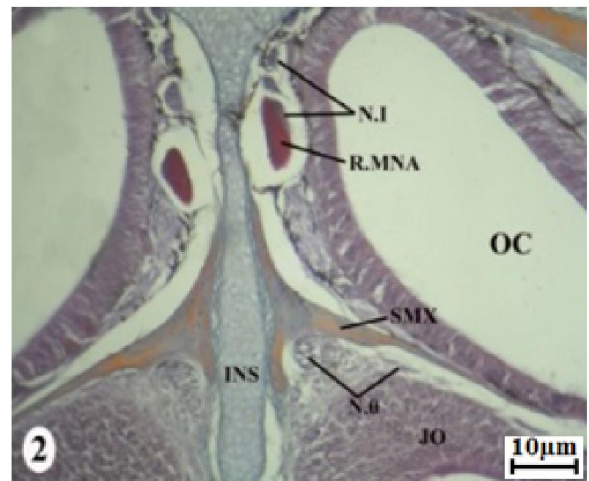
**nervi terminalis and vomeronasalis**

In *Chacidessepoides*, the nervus terminalis arises in the form of nerve fibres from the dorsal and dorsomedial sides of the anterior part of jacobson's organ in association with the nervusvomeronasalis (Fig. 1). These fibres extend posterodorsally passing dorsal to the latter organ and ventral to the septomaxillary bone. These fibres progressively close each other forming one large bundle that through the septomaxillary bone to enter the nasal region (Figs. 2&3).

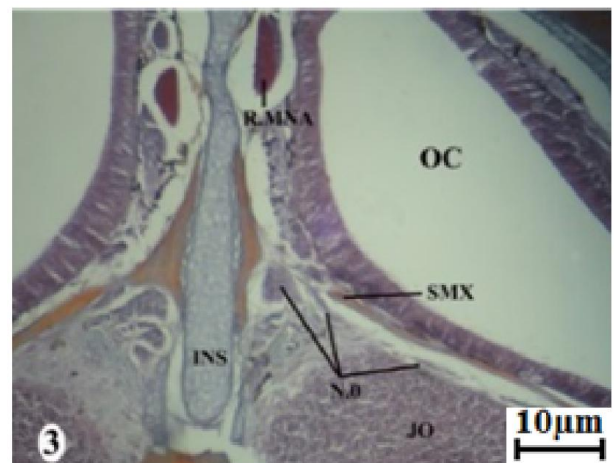

**Fig. 1.** Photomicrograph of a part of transverse section passing through the anterior olfactory region of *Chacidessepoides* showing the origin of the terminal nerve fibres (N.0), the septomaxillary bone (SM) forming the roof of Jacobson's organ (J.O), nervusolfactorius (N.I), olfactory chamber (OC), nasal bone (NA), internasal septum (INS), ramus medialisnasi. Scale bar= 35.71

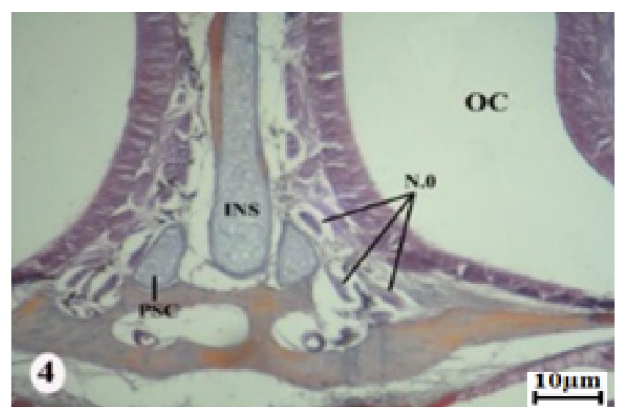
From the dorsal side of the middle part of Jacobson's organ, additional nerve fibres are formed. These nerve fibres approach each other to be another bundle that fused with the first one (Fig. 3).



**Fig. 2.** Photomicrograph of a part of transverse section passing through the anterior olfactory region of *Chacidessepoides* elucidating the formation of the first bundle of the nervus terminalis. Scale bar= 25



**Fig. 3.** Photomicrograph of a part of transverse section passing through the anterior olfactory region and the middle region of the vomeronasal organ of *Chacidessepoides* illustrating the passage of the terminal nerve bundle through the septomaxillary bone. Scale bar= 25



**Fig. 4.** Photomicrograph of a part of transverse section passing through the anterior olfactory region and the caudal region of Jacobson's organ of *Chacidessepoides* showing the passage of the terminal nerve bundles through the nasal region, paraseptal cartilage (PSC). Scale bar= 25

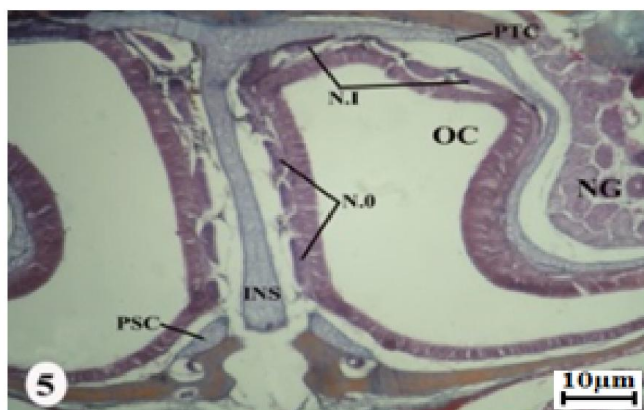


Fig. 5. Photomicrograph of a part of transverse section passing through the olfactory region of *Chacidessepoides* showing the passage of the terminal nerve within the olfactory capsule, nasal gland (NG). Scale bar= 35.7

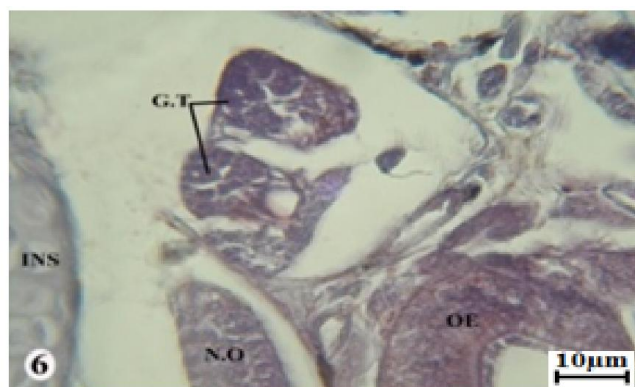


Fig. 6. Photomicrograph of a part of transverse section passing through the olfactory region of *Chacidessepoides* showing the ganglion terminale (G.T). Scale bar= 6.25

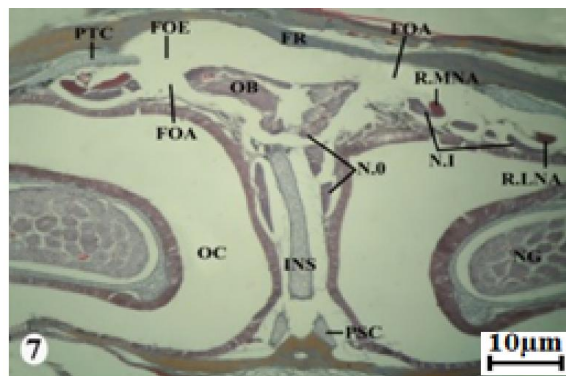


Fig. 7. Photomicrograph of a part of transverse section passing through the post olfactory region of *Chacidessepoides* showing the exits of the terminal nerve from the olfactory capsule through the fenestra olfactoriumadvehens (FOA) and its entrance to the cranial cavity through the fenestra olfactoriumevehens (FOE), accessory olfactory bulb (AOB). Scale bar= 62.5

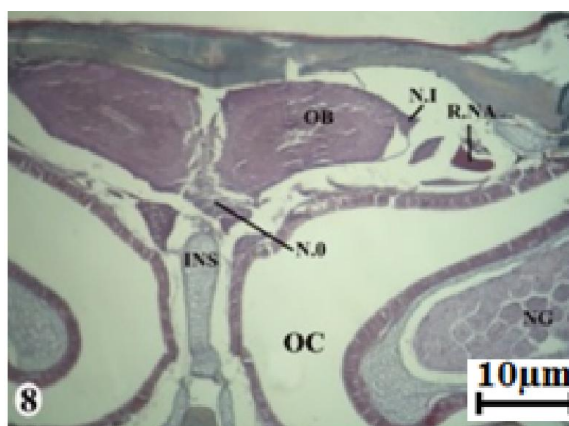


Fig. 8. Photomicrograph of a part of transverse section passing through the most posterior olfactory region of *Chacidessepoides* showing entrance of the terminal nerves into the accessory olfactory bulbs and the posterolateral part of the olfactory bulb. Scale bar= 50

There are nerve fibres are arised from the posterior part of Jacobson's organ, passing ventral to the first bundle and forming two bundles (Fig. 4). The three bundles extend posterodorsally and enter the nasal region passing dorsal to the paraseptal cartilage, medial to the olfactory epithelium, ventral to the nervusolfactorius and lateral to internasal (Figs. 4&5). From the caudal region of the vomernasal organ, there are additional fascicles are added (Fig. 4). These fascicles aggregate forming another bundle. Subsequent to Jacobson's organ, the four bundles extend posteriorly and enter the nasal capsule passing along the medial side of the olfactory organ dorsal to the paraseptal cartilage and prevomer boneand lateral to the internasal septum (Fig. 5). After a psterodorsal course the nervus terminalis leaves the nasal capsule through the fenestra olfactoriumadvehens. Within the latter foramen, there is some ganglionic cells are formed which represent the ganglion terminale (Fig. 6).After a short extra capsular path, the nervus terminalis enters the encephalic cavity through the fenestra olfactoriumevehens (Fig. 7). Intracranially, the nervus terminalis extend posteriorly ventromedial to the olfactory bulb (Fig. 8). Thereafter, they shift posterodorsally passing medial to the main olfactory. The terminal connects with the outer layer of the brain, but the vomeronasal one enters the accessory olfactory bulbs (vomeronasal formation) from its ventromedial side. The latter structure is located poster medial to the main olfactory bulb.

### Nervusolfactorius

The nervusolfactorius is a special sensory nerve as its fibres are formed by the cells of the sensory olfactory epithelium rather than by the nervous system elements. In *Chacidessepoides*, the originating nerve fibres aggregate in several fine branches (Fig. 1). These branches extend posteriorly within the nasal capsule along both the dorsal and medial sides of the olfactory epithelium. As they run backwards, the nerve fibres converge each other constitute many nerve bundles. These bundles extend posteriorly in a dorsal direction passing dorsal to the ramus medialisnasi of the nervus trigeminus, lateral to the internasal septum, ventral to the nasal bone and medial to the olfactory organ (Fig. 1). During their posterior passage, the nervusolfactorius touches the ramus medialisnasi without anastomosis between their fibres (Fig. 2). The nerve bundles extend laterally to be dorsal to the olfactory apparatus and ventral to the parietotectal cartilage (Fig. 5). Slightly backwards, the nerve bundles leave the nasal capsule through the foramen olfactoriumadvehens (Fig. 7) and enter the cranial cavity to attach the olfactory bulb from its dorsolateral sides (Fig. 8). There is no olfactory peduncle.

## DISCUSSION

The examination of the olfactory innervation in *Chacideseppoides*, revealed the presence of three types of nerve fibres that comprise the nervi terminalis, vomeronasalis and olfactorius which arise from Jacobson's organ and olfactory apparatus respectively. The fibres of the nervus terminalis differ from those of the other two latter nerves. This nerve was specified in all vertebrate classes except in cyclostomes and birds as reported by Haller von Hallerstein (1934), Shamakh (2009), Dakrory (2011) and Mahgoub (2014). However, the terminal nerve was found in lampreys, follows the application of horseradish peroxidase to the olfactory mucosa (Von Bartheld et al., 1987 and Northcutt and Puzdrowski, 1988). Some anatomists proposed that this nerve is probably a ganglionated residue of an anterior branchial nerve which innervated the mouth region (Romer and Parsons, 1985; Goodrich, 1986).

In the current study, the nervus terminalis originated from the epithelium of Jacobson's organ in association with the nervus vomeronasalis. The fibres of those two nerves continue together during their course through the olfactory capsule and the intracranial cavity. Similar results were observed in the lizards *Laudakiastellio* (Shamakh, 2009), *Mesalinaquuttulata* (Mahgoub, 2014) and in the serpents *Najahajehaje* (Abdel-Kader et al 2000) and *Coluberrogersi* (Omar, 2013). The emanation of the nervus terminalis together with the vomeronal one was comparable to that present in mammals as in cats and dogs (Mc Cotter, 1913) and in the hedgehog (Hegazy 1990). However, the course of the two latter nerves was disagreed with those present in the serpents studied by Hegazy (1976) and Mostafa (1990).

In *Chacideseppoides*, a gather of ganglionic cells are formed in two of the four bundles of the nervus terminalis. These cells are formed within the foramen olfactorium advehens and represent the ganglion terminale as denominated by Döllken (1909). The disposition of the ganglion terminale that present in this study differs than was reported by Shamakh (2009), Dakrory (2011) and Mahgoub (2014). These authors mentioned that the ganglion terminale arises within the nasal capsule. Also, the configuration of the latter ganglion entirely differ from that recorded by Hegazy (1976) and Mostafa (1990) in ophidian which registered the intracranial position of the ganglion terminale. One or two ganglia terminale present in the nervus terminalis of fishes, amphibians, reptiles and mammals (Haller von Hallerstein, 1934; Goodrich, 1986 and Dakrory, 1994).

In the existent study, the vomeronasal nerve is united with the vomeronasal organ from one hand and linked to the olfactory bulb formation from the other hand. A comparable observation was described in the lizards studied by Dakrory (1994), El-Gareeb (1997) and Shamakh (2009) and in snakes demonstrated by Abdel-kader et al (2000), Mahgoub (2004) and Omar (2013). This case appears to be a common character in Sphenodon and squamates (Bellairs, 1950 and Jollie, 1968). The vomeronasal nerve, Jacobson's olfactory organ and the accessory olfactory bulbs are not located in chelonians and crocodylian and in all birds (Watanabe and Yasuda, 1968; Soliman et al., 1986).

In many mammals as various bats, whales, in some carnivorous and in man and the other higher primates as *maquque*, there is no accessory olfactory bulb due to the absence of the vomeronasal organ (Romer and Parsons, 1985). In *Chacideseppoides*, the three nerves under investigation leave the olfactory capsule through the foramen olfactorium advehens. This foramen is formed due to the connection between the planum orbitale and the nasal septum. This closed foramen appears to be found in most lizards so far described. It is reported by Rice (1920) in *Eumeces*, De Beer (1937) in *Lacerta*, and by Ramaswami (1946) in *Calotes*. However, this foramen appears as a wide incisura instead of a closed foramen in the amphibaenian *Diplometoponzarudnyi*. This configuration because the absence of fusion between the planum orbitale and the nasal septum (Dakrory, 1994). In ophidians, the two cases were recorded either a closed foramen as in *Najahaje* (Abdel-Kader et al., 2000) and *Coluberrogersi* (Omar, 2013) or a wide incisure rather than a complete foramen in the snakes *Psammophis sibilans* and *Eryx jaculus* (Hegazy, 1976) and in both *Psammophis schokari* and *Coluberelegantissimus* (Mostafa, 1990).

In agamid lizards, the three nervi terminalis, vomeronasalis and olfactorius leave the olfactory capsule in the form of separate bundles each one exits from its own foramen. It was observed in *Agama atra* (Malan, 1946), *Agama hispida* (Barry, 1953), *Agama stellio* (Eyal-Giladi, 1964) and in *Laudakiastellio* (Shamakh, 2009). In birds, a defined fenestra olfactoria advehens seems to be present (Soliman et al., 1986). But, the nervus olfactorius leaves the capsular cavity through an undelimited fenestra in *Anas boschas* (De Beer, 1937), fissura orbitonasalis in *Sternus vulgaris* (De Kock, 1955) and by means of a bony canal in *Colius indicus* (Schoonees, 1963). In Mammalia, the fenestra olfactoria advehens (fenestra cribrosa) is subdivided into numerous pores of the cribriform plate (De Beer, 1937; Jollie, 1968; Hegazy, 1990). Here, the nervi terminalis, vomeronasalis and olfactorius enters the cranial cavity through the fenestra olfactoria advehens. Similar results were seen in *Laudakiastellio* (Shamakh, 2009) and in *Varanus niloticus* (Dakrory, 2011). In rare cases of lacerilians, the latter fenestra is absent and the three nervi under question become intracranially through their passage into a membranous cranial wall as in *Diplometoponzarudnyi* (Dakrory, 1994). In Ophidia, the absence of the fenestra olfactoria advehens appears to be general (Abdel-Kader et al., 2000, Omar, 2013).

## Conclusion

The olfactory apparatus gives off three types of nerves that orderly into the nervi terminalis and vomeronasalis arising from the accessory olfactory system (Jacobson's organ) and the nervus olfactorius originating from the main olfactory organ.

## Acknowledgements

Support and facilities for my investigations of this research were graciously provided at the Zoology Department, Faculty of Science, and Cairo University. I also wish to thank my close friend for her continued support.

## REFERENCES

- Abdel-Kader, I.Y. 2006. The cranial nerves of the cat snake *Telescopus dhara* (Colubridae, Ophidia): I. The eye muscle nerves and the ciliary ganglion. *J. Egypt. Ger. Soc. Zool.*, 50(B): 1-16.
- Abdel-Kader, I.Y., Soliman, M.A. and Hegazy, R.M. 2000. Innervation of the nasal region of the Egyptian cobra *Najahajahaja*. *J. Egypt. Ger. Soc. Zool.*, 33:57-76.
- Abdel-Kader, T.G., Shamakh, A.A and Dakrory, A.I. 2007. The cranial nerves of *Mabuya quinqueaeniata*. I. The eye muscle nerves and the ciliary ganglion. *Egypt. J. Zool.*, 49:193-209.
- Barry, T.H. 1953. Contribution to the cranial morphology of *Agama hispida* (Linn.). *Ann. Univ. Stellenbosch*, 29(A) 2: 55-57.
- Bellairs, A.d'A. 1950. Observation on the cranial anatomy of *Anniella*, and a comparison with that of other burrowing lizards. *Proc. Zool. Soc. Lond.*, 119(4):887-904.
- Dakrory, A.I. 1994. Anatomical studies on the cranial nerves of Amphisbaenian (*Diplometopon zarudnyi*). M. Sc. Thesis, *Fac. Sci. Cairo Univ. Egypt*.
- Dakrory, A.I. 2011. Innervation of the Olfactory Apparatus of *Varanus Niloticus* (Squamata– Lacertilia- Varanidae). *Journal of American Science*, 7(9): 118-125.
- Daniels, C.B and Heatwole, H. 1990. Factors affecting the escape behavior of a reptilian lizard. *Mem. Queensland Mus.* 29: 375- 387.
- De Beer, G.R. 1937. *The Development of the Vertebrate Skull*. Clarendon Press, Oxford, UK.
- De Kock, J.M. 1955. The cranial morphology of *Sturnus vulgaris vulgaris* Linnaeus. *Ann. Univ. Stellenbosch*, 31(A) 3: 153-177.
- Disi, M., Werner, Y. and El Din, S.B. 2006. *Chalcidessespoides*. The IUCN Red List of Threatened Species 2006: e.T61571A12518031.
- Döllken, A. 1909. Ursprung Centren des Nervus terminalis. *Monats.f. Psych. U. Neur., Erg. Bd.*, 26: 10-33.
- El-Ghareeb, A.A, Abdel-Kader, I. Y and Mahgoub, A.F. 2004. The cranial nerves of the snake *Natrix tessellate* (Ophidia, Colubridae). The eye muscle nerves, and the ciliary ganglion. *J. Union Arab Biol. Cairo*, 22(A): 305-330.
- El-Ghareeb, A.A. 1997. Anatomical studies on the cranial nerves of the lizard *Acanthodactylus boskianus* (Daud). Ph. D. Thesis, *Fac. Sci., Cairo Univ., Egypt*.
- Eyal-Giladi, H. 1964. The development of the chondrocranium of *Agama stellio*. *Acta Zool.*, 45: 139-165.
- Goodrich, E.S. 1986. *The Structure and Development of Vertebrates*. Maxmillan and Co. London, UK.
- Haller von Hallerstein, V. 1934. *Anatomie der Wirbeltiere 2/1*, herausgegeben von Bolk, Göppert, Kallius, Lubosch. Berlin und Wien.
- Hegazy, M.A. 1976. Comparative Anatomical studies on the cranial nerves of Ophidia. Ph. D. Thesis, *Fac. Sci., Cairo Univ. Egypt*.
- Hegazy, M.A. 1990. A contribution to the anatomy of the vomeronasal organ of Jacobson of mammals with special reference to the Insectivore *Hemiechinus aeuritus* (Gmelin). *Proc. Zool. Soc. A. R. E.*, 19:33-50.
- Hegazy, M.A. 1990. A contribution to the Anatomy of the vomeronasal organ of Jacobson of Mammals with special reference to the Insectivore *Hemiechinus aeuritus* (Gmelin). *Proc. Zool. Soc. A. R. E.*, 19: 33-50.
- Jollie, M.T. 1968. The head skeleton of a new-born *Manis javanica* with comment on the ontogeny and phylogeny of the mammal head skeleton. *Acta Zool.*, 49: 227-305.
- Mahgoub, A.F. 2004. Anatomical studies on the cranial nerves of the snake *Natrix tessellate*. Ph. D. Thesis, *Fac. Sci., Cairo Univ.*
- Mahgoub, A.F. 2014. Innervation of the Olfactory Apparatus of *Mesalina Quttulata* (Squamata–Lacertilia–Lacertidae). International Conference of Agriculture, Environmental and Biological Sciences (ICFAE'14) June 4-5, 2014 Antalya (Turkey)
- Malan, M.E. 1946. Contributions to a comparative anatomy of the nasal capsule and organ of Jacobson of Lacertilia. *Ann. Univ. Stellenbosch*, 24(A): 69-137.
- McCotter, R.E. 1913. The nervus terminalis in the adult dog and cat. *J. Comp. Neurol.*, 23(2): 145-152.
- Mecke, S., Doughty, P. and Donnellan, S.C. 2013. "Redescription of *Eremiascincus fasciolatus* (Günther, 1867) (Reptilia: Squamata: Scincidae) with clarification of its synonyms and the description of a new species". *Zootaxa* 3701 (5): 473–517.
- Mostafa, R.H. 1990. The nervi terminalis, vomeronasalis and olfactorius in Ophidia. *Egypt. J. Anat.*, 13(2):259-269.
- Northcutt, R.G and Puzdrowski, R.L. 1988. Projections of the olfactory bulb and nervus terminalis in the silver lamprey. *Brain Behav. Evol.*, 32: 96-107.
- Omar, A.R. 2013. Anatomical Studies on the Cranial Nerves of the Snake *Coluber rogersi*. Ph.D. Thesis, *Fac. Sci. Cairo Univ. Egypt*.
- Omar, A.R., Riad, A.M., Dakrory, A.I., AbdelKader, I.Y. and Mahmoud, A.A. 2015. Eye muscle nerves and the ciliary ganglion of *Malpolon monspessulana* (Colubridae, Ophidia). *The Journal of Basic & Applied Zoology*, 70, 41–52.
- Ramaswami, L.S. 1946. The chondrocranium of *Calotes versicolor* (Daud.) with a description of the osteocranium of a just-hatched young. *Quart. J. Micr. Sci.*, 87:237-297.
- Rice, E.L. 1920. The development of the skull in the skink, *Eumeces quinelineatus*. *J. Morph.*, 34: 119 -220.
- Romer, A.S. and Parsons, T.S. 1985. *The Vertebrate Body*, 6th edit. W. B. Saunders Co. Philadelphia and London.
- Schoonees. 1963. Some aspects of the cranial morphology of *Colius indicus*. *Ann Univ Stellenbosch*, 38: 215-246.
- Shamakh, A.A. 2009. Innervation of the olfactory apparatus of *Laudakiastellio* (Reptilia – Squamata – Agamidae). *Egypt. J. Zool.*, 52:453-469.
- Soliman, M.A., Hegazy, M.A. and Mostafa, R.H. 1986. The cranial nerves of Birds. II. The main special sensory nerves, nervus olfactorius, nervus opticus and nervus octavus. *Proc. Zool. Soc. A.R.E.*, 10:211-232.
- Von Bartheld, C.S., Lindorfer, H.W. and Meyer, D.L. 1987. The nervus terminalis also exists in cyclostomes and birds. *Cell Tissue Res.*, 244:181-186.
- Watanabe, T. and Yasuda, M. 1968. Comparative and Topographical anatomy of the fowl: II. Peripheral course of the olfactory nerve in the fowl. *Jap. J. Vetr. Sci.*, 30:275-279.

\*\*\*\*\*