



ISSN: 2230-9926

Available online at <http://www.journalijdr.com>

# IJDR

International Journal of Development Research  
Vol. 11, Issue, 12, pp. 52996-53001, December, 2021  
<https://doi.org/10.37118/ijdr.23692.12.2021>



RESEARCH ARTICLE

OPEN ACCESS

## A CLINICAL STUDY ON UNILATERAL PROPTOSIS : THE EVER EXPANDING ENT SPECTRUM

Sapna S Nambiar\*<sup>1</sup> and Suma, R.<sup>2</sup>

<sup>1</sup>Assistant Professor, Dept of Otorhinolaryngology Govt Medical College Kozhikode, Kerala, India 673008

<sup>2</sup>Addl Professor, Dept of Otorhinolaryngology Govt Medical College Manjeri, Kerala, India

### ARTICLE INFO

#### Article History:

Received 03<sup>rd</sup> September, 2021  
Received in revised form  
11<sup>th</sup> October, 2021  
Accepted 14<sup>th</sup> November, 2021  
Published online 30<sup>th</sup> December, 2021

#### Key Words:

Paranasal Sinus Diseases,  
Proptosis,  
Nasal Endoscopy, Imaging.

\*Corresponding author: Sapna S Nambiar,

### ABSTRACT

**Background:** Proptosis is a sign in search for a diagnosis. Though a common manifestation of orbital pathology it could be an early and at times only manifestation in patients with nasal and paranasal sinus pathology. This makes the role of an Otorhinolaryngologist important with endoscopes having revolutionized the management of these patients. **Method:** The clinical study was conducted at the Department of ENT, Government Medical College Kozhikode over a period of one year using convenience sampling. All patients with unilateral proptosis satisfying the inclusion criteria were completely evaluated with history and clinical examination followed by relevant investigations including imaging to reach the diagnosis. **Results:** In our study 38% patients had malignancies of nose and paranasal sinuses and 62% benign, inflammatory lesions. This sign was common in patients in the 5<sup>th</sup> & 6<sup>th</sup> decade of life and more in men irrespective of the etiology. Nasal obstruction was the predominant symptom. Imaging helped in evaluating the extent of the lesion and planning the approach in surgery. **Conclusion:** Proptosis is a sign that requires a multidisciplinary approach for appropriate diagnosis and treatment. It is necessary to be able to diagnose neoplastic lesions of nasal and paranasal sinuses from other inflammatory and benign lesions. Nasal endoscopy with biopsy is the gold standard in diagnosis.

Copyright © 2021, Sapna S Nambiar and Suma, R. This is an open access article distributed under the Creative Commons Attribution License, which permits unrestricted use, distribution, and reproduction in any medium, provided the original work is properly cited.

Citation: Sapna S Nambiar and Suma, R. "A clinical study on unilateral proptosis: the ever expanding ENT spectrum", *International Journal of Development Research*, 11, (12), 52996-53001.

## INTRODUCTION

Proptosis is one of the common manifestations of orbital pathology. The difficulties associated with approaching the orbit are related to its relatively small volume, irregular pyramidal shape and location embedded in craniofacial structures. The eye is a major crossroad for all the structures around it which help in its support and functioning, which when affected extends into the orbit causing proptosis (Susan Dsouza, 2017). Therefore proptosis could at times be an early and sometimes only manifestation of nasal or paranasal sinus pathology. A wide spectrum of conditions in ENT; including inflammatory diseases, benign lesions and malignancies can present with unilateral proptosis. The signs and symptoms of such lesions may be non-specific and do not help directly in reaching a diagnosis. Many of the lesions cannot be examined directly since these are neither visible nor palpable; moreover surgical exploration of orbit is an invasive procedure which may lead to various ophthalmic complications. The role of an otorhinolaryngologist is crucial in evaluation of a patient with unilateral proptosis especially so with the advent of the use of endoscopes.

The ever expanding clinical spectrum highlights the challenging situations faced in diagnosing and treating patients with unilateral proptosis.

## MATERIAL AND METHODS

This longitudinal study comprised of all the patients with unilateral proptosis presenting to the Department of ENT, Government Medical College Kozhikode; a tertiary care hospital in the northern part of Kerala for a period of one year from Oct 2016 to Sep 2017.

**Study sample:** All patients with unilateral proptosis presenting to the ENT outpatient department and admitted patients referred from other departments were included.

**Inclusion criteria:** Patients with unilateral proptosis seen in the department of ENT from Oct 2016 to Sep 2017 were included in the study.

**Exclusion criteria:** Patients with bilateral proptosis, pseudoproptosis, those diagnosed with primary orbital pathology, bedridden, debilitated and those not willing to participate were excluded from the study.

**Patient evaluation:** All patients who satisfied inclusion and exclusion criteria were interviewed with a pretested and validated schedule and clinical evaluation of proptosis was done after taking informed consent. Every case was followed till the end of treatment.

**Clinical evaluation:** A complete history with clinical evaluation was done for all the patients including Ophthalmology examination. The detailed history included onset, duration and rate of progression of proptosis with visual acuity, color vision, pupillary reaction, extra-ocular movements also examined. The patients underwent nasal endoscopy with biopsy after a contrast enhanced CT scan nose and paranasal sinuses. In patients with extension of the lesion into orbit or intracranial cavity, an MRI orbit or brain respectively with nose and paranasal sinuses was done for evaluating the extent of the disease and likely pathology. The final diagnosis was made after the histopathology report was obtained and treatment modality planned accordingly. The patients were evaluated after treatment at 2 weeks, 1 month, 3 months, 6months and one year. Thereafter yearly evaluation was advised as on required basis till completion of treatment.

**Statistical analysis:** The demographic data, clinical symptoms and radiological findings were compared between the patients with benign, inflammatory lesions and malignant lesions that presented with unilateral proptosis. The data was collected and analysed statistically using Chi-square test. The level of significance was  $p < 0.05$ .

**Ethical issues:** Institutional review board and ethics committee Government Medical College Kozhikode approved the study protocol. Informed written consent was taken from all the study participants.

## RESULTS

The clinical study included 21 patients with unilateral proptosis during the period from Oct 2016 to Sep 2017. All the patients with unilateral proptosis having malignancies of nose and paranasal sinuses were found to be over 50 years of age whereas 4 (30.7%) patients were below 50 years of age in the inflammatory, benign group with the youngest child being 3 years of age. (Table 1).

**Table No. 1. Age distribution comparing the two groups**  
Total cases: 21

Age groups (years)	Benign/ Inflammatory lesions n= 13(62%)	Malignant lesions n = 8 (38%)
0-25	3	0
26-50	1	0
51-75	9	8

**Table No. 2. Sex distribution comparing the two groups**

Sex	Benign/ Inflammatory lesions n =13(62%)	Malignant Lesions n=8 (38%)
Male	9	6
Female	4	2

There were 15 (71%) males and 6(29%) females. On analysis of the gender of patients; 9(69.2%) were males and 4 (30.8%) females in the benign lesions and inflammatory group and similarly 6 (75%) were males and 2(25%) were females in the malignant group. (Table 2) Thus in our study males predominantly presented with unilateral proptosis irrespective of the etiology. Of the 21 patients; 8 (38%) had malignancies of the nose and paranasal sinuses and 13 (62%) had inflammatory and benign lesions. Fronto-ethmoid mucocele was the commonest of the benign conditions and squamous cell carcinoma of nose and paranasal sinuses, the commonest of the malignancies to present with unilateral proptosis.

(Table 3) Unilateral proptosis is a sign common to both benign and malignant conditions of the nose and paranasal sinuses thereby requiring further evaluation and investigations for arriving at the appropriate diagnosis.

**Table 3. Distribution of various pathologies diagnosed**

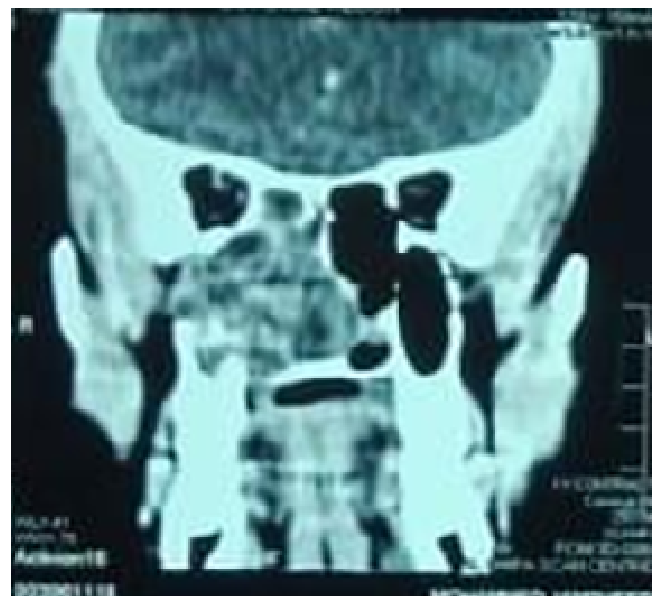Benign lesions ( n = 13)	
Frontoethmoid mucoceles	4 (30.7%)
Fungal Rhinisinusitis	2 (15.4%)
Inverted papilloma	2 (15.4%)
Aneurysmal bone cyst	1 (7.7%)
Inflammatory pseudotumor	1 (7.7%)
Fibrous dysplasia	1 (7.7%)
Grave's disease	1 (7.7%)
Meningioma	1 (7.7%)
Malignancies ( n = 8)	
Squamous cell carcinoma	5 (62.5%)
Adenocarcinoma	1 (12.5%)
NHL (Non Hodgkin's lymphoma)	1 (12.5%)
Adenoid cystic carcinoma	1 (12.5%)

On analysis of the various symptoms of the patients; nasal obstruction was the commonest symptom among both the groups. Epistaxis was a symptom found to be statistically significant ( $p=0.0063$ ) in patients with malignancies whereas epiphora was the symptom found to be statistically significant ( $p=0.0274$ ) in patients in the inflammatory, benign conditions group (Table 4).

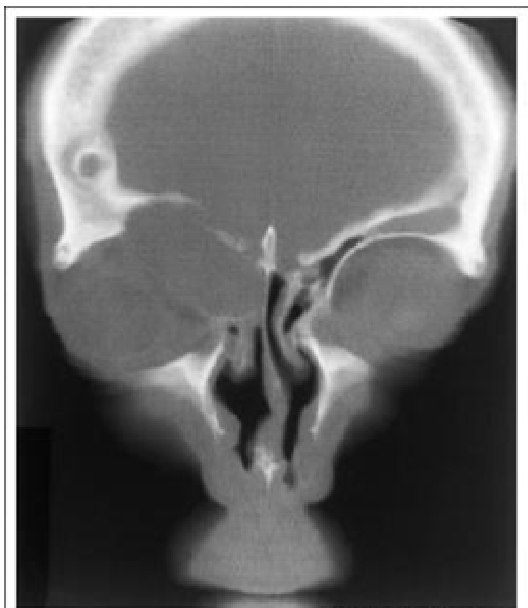**Table No 4. Distribution of various symptoms in the patients**

Symptoms	Benign lesions	Malignant lesion	P-Value
Nasal Obstruction	11	6	0.5858
Nasal discharge	7	5	0.6972
Epistaxis	2	6	0.0063
Headache and facial pain	5	6	0.1035
Facial swelling	2	4	0.0882
Hyposmia	3	4	0.2037
Orbital complaints Epiphora	8	1	0.0274
Diplopia	4	2	0.7763
Dimness of vision	2	1	0.8544
Dental complaints	3	2	0.9200

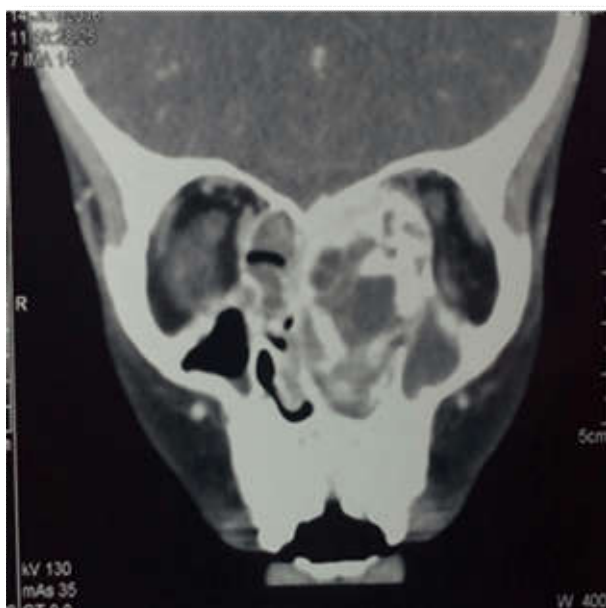The contrast enhanced CT scan findings revealed sinus opacity with bony erosions and destruction resulting in early involvement of adjacent structures like the orbit and or skull base in malignancies of the nose and paranasal sinuses. (Fig 1) The benign lesions like mucoceles (Fig 2) and fibro-osseous diseases (Fig 3) did reveal bony expansion and thinning with extension to adjacent structures mimicking malignancy.



**Fig 1. CT scan showing extensive bone destruction in a patient with adenoid cystic carcinoma of maxillary sinus (Rt)**



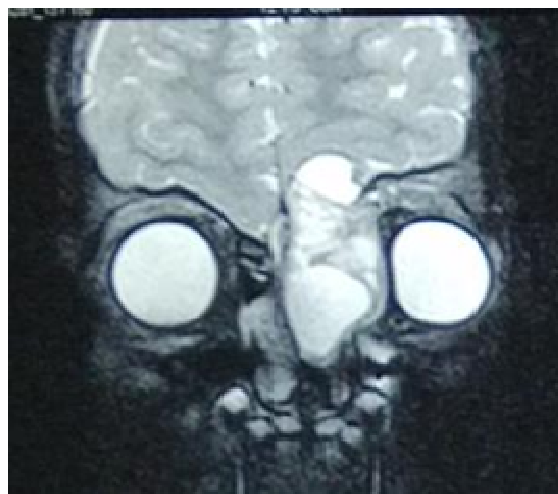**Fig 2. CT scan in a patient with frontoethmoid mucocoele showing expansile lesion in right frontal sinus with bony erosion of the floor of the frontal sinus**



**Fig 3: CT scan in a patient with fibrous dysplasia showing expansile lesion with orbital extension**

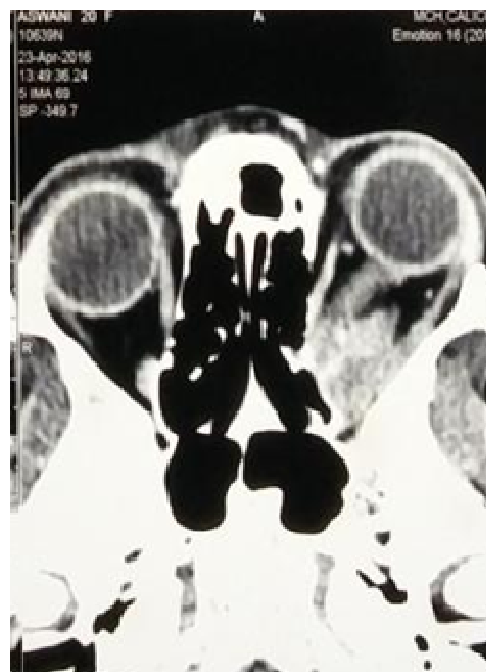The MRI of orbit and brain did help to ascertain the extent of the disease prior to treatment. Though challenging in children, our 3 year old patient with aneurysmal bone cyst had an MRI which revealed intracranial extension dictating a combined approach for complete excision (Fig 4) The radiological investigations though important in diagnosis had grey areas where a few benign lesions could mimic a malignancy and malignant lesions in early stages could be mistaken for a benign condition.

Our patient with meningioma had the contrast enhanced CT scan showing erosion of the greater wing of sphenoid with lesion extending to the paracavernous region and anterior part of middle cranial fossa.(Fig 5)The MRI showed a T2 hyperintense mass lesion involving the retro orbital intraconal compartment displacing the optic nerve inferomedially, inseparable from the extra ocular muscles at the orbital apex (Fig 6) Though radiologically suggestive of a lymphoproliferative lesion it was the biopsy that helped clinch the diagnosis of meningioma enabling treatment.



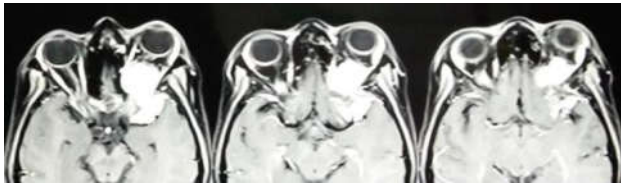
**Fig 4. MRI in our patient with aneurysmal bone cyst showing multilocular cystic lesion with both intracranial and orbital extension**

The radiological findings as seen on CT scan of nose, paranasal sinuses and orbit in patients with proptosis is as summarized in Fig. 9 wherein aggressive bone destruction and involvement of adjacent structures though characteristic of malignant lesions can be found in many benign conditions too which is what makes the diagnosis challenging. In such cases a clinico-radiological co-relation necessitating a nasal endoscopy with biopsy is essential to make the final diagnosis.

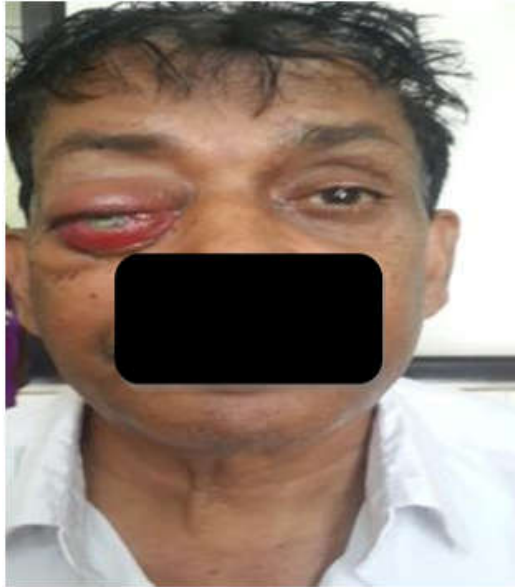

**Fig 5. CT scan in the patient with meningioma showing lesion in the retro-orbital intraconal compartment with erosion of greater wing of sphenoid**

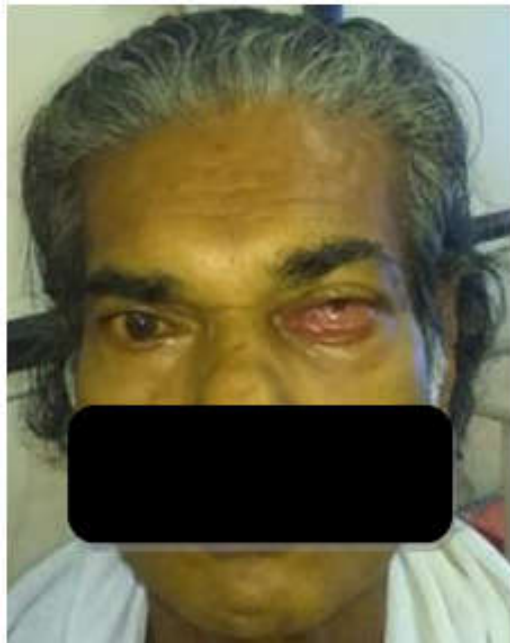Nasal endoscopy with biopsy forms the mainstay in diagnosis. The histopathological features, with immunohistochemistry(IHC) if required confirms the diagnosis. Obtaining a nasal biopsy can be challenging and requires expertise; as in our patient with meningioma where endoscopic sinus surgery inclusive of an ethmoidectomy, removal of the lamina papyracea, incision of the orbital periosteum and meticulous retraction of medial rectus was required to visualize the lesion that was within the orbit pushing the optic nerve inferomedially. This is where the endoscope can help make the difference enabling biopsy with least morbidity and utmost patient compliance.



**Fig 6. MRI in the patient with meningioma showing T2 hyperintense mass lesion in retro-orbital, intraconal compartment extending to paracavernous region and anterior part of middle cranial fossa**

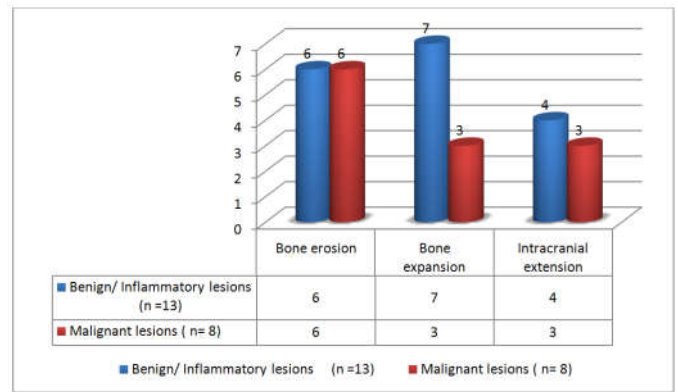


**Fig. 7. Eccentric proptosis in a patient with frontoethmoid mucocele**



**Fig. 8. Axial proptosis in a patient with Inflammatory pseudotumor**

The biopsy if taken inappropriately can result in erroneous reports and a deep biopsy from the representative sample is mandatory for the correct diagnosis. Our patients with adenoid cystic carcinoma and aneurysmal bone cyst were referred with excessive bleeding during the procedure of attempted nasal biopsy in the peripheral hospitals with the obtained specimen result of an angiofibroma.



**Fig. 9. CT scan findings**

Therefore the procedure of diagnostic nasal endoscopy (DNE) with biopsy must be performed judiciously with facilities to manage likely complications. The treatment is then planned with the modality best suited and in cases requiring surgery the approach is decided. In our study medical management in patients with Grave's disease and IgG4 related inflammatory pseudotumor helped recovery. Surgery was advised in patients with mucoceles, fibrous dysplasia and inverted papilloma where the endoscopic approach was used for the excision of lesions. The endoscope enabled surgery with utmost precision due to the magnified view, clarity and close proximity possible to the lesion. The patient diagnosed with meningioma following biopsy underwent craniotomy with excision by the neurosurgeon and the child diagnosed with aneurysmal bone cyst underwent a combined approach surgery with both the otorhinolaryngologist and neurosurgeon ensuring complete excision and closure of the defect in the skull base. The above cases highlight the significance of the multidisciplinary approach required in patients presenting with proptosis. Patients diagnosed with malignancies were staged and treatment with surgery, chemotherapy, radiotherapy or combined modality instituted as was deemed necessary by the tumour board. Patient with Non Hodgkin's lymphoma received chemotherapy whereas patient with adenoid cystic carcinoma underwent extended total maxillectomy followed by radiotherapy.

## DISCUSSION

A patient presenting with unilateral proptosis poses a clinical challenge on account of the varied differences in etiology. Invariably most of them present to the Ophthalmology department wherein they are completely evaluated to rule out any local pathology and then referred once local cause is ruled out. Proptosis is defined as a forward movement of the globe in relation to the skull and generally measured by the protrusion of the apex of the cornea in front of the outer orbital margin while the eye looks straight ahead (Kumar, 1999). The proximity and intimacy of the eye to the nose and paranasal sinuses; structures related to support and help functioning of the globe, will lead to extension of diseases into the orbit and ultimately proptosis. Various ENT diseases may manifest as proptosis but the signs and symptoms of such lesions may be nonspecific and do not help directly in reaching a diagnosis. Many of the lesions cannot be examined directly since these are neither visible nor palpable; moreover surgical exploration of orbit is an invasive procedure which may lead to various ophthalmic complications (Keche, 2013). Proptosis is a sign noted in cases of both malignant and benign lesions of the nose and paranasal sinuses.

Therefore it is necessary to find ways to be able to diagnose the etiology earlier thereby enabling appropriate treatment and reduction in morbidity. Malignancies (50%) and benign tumour and tumour like lesions (45%) were the main cause of unilateral proptosis in nearly 95% of the cases in the study by Kumar RD unlike Merchant (1993) who found that in 45.5%, the lesions were due to infections. Malignancies accounted for 41% and bleeding diathesis for 13.5% (Kumar, 1999; Merchant, 1993). In our study malignancies of nose

and paranasal sinuses accounted for 38% cases and 62% were due to benign conditions. These findings are corroborated by studies conducted by Zaidi S H. (1991) Dallow et al. (2003) and Mallajoysula S 2009. Inflammatory orbital disorders (thyroid eye disease and other inflammatory diseases) were the major etiology of proptosis affecting those between 20–60 years with steady decline in extreme of ages. The average volume of an adult orbit is 30ml. An increase of orbital volume by only 5ml will produce 4-5mm of proptosis. Clinically significant proptosis is any forward displacement of globe 2mm greater than the other as measured by Hertel's/Krahn exophthalmometer (Sinha, 2005). An orbital mass will typically displace the globe opposite the direction it originates from, unless there is axial proptosis (eye protrudes directly forward), indicating a lesion within the muscle cone of the orbit/directly behind the globe (Nicole, 2020). In frontoethmoid mucoceles the globe is displaced laterally and/or inferiorly, in case of lesions from the maxillary sinus the globe is pushed superiorly, lesions within the orbit cause axial proptosis and lesions of the temporal fossa cause a medial displacement of the globe (Sinha, 2005). In our study too, patients with frontoethmoid mucoceles had the globe displaced outwards and inferiorly (Fig 7) whereas lesions in the maxillary sinus and nasal cavity displaced it outwards and superiorly (Fig 8). The anatomical situation of the orbits results in lesions which are of interest to neurosurgeon as well as rhinologist (Mohan, 1968). The history in evaluation of patients with unilateral proptosis must include the onset, progression and presence of associated signs and symptoms such as fever, pain, visual loss and diplopia. A history of allergies, sinus infection, epistaxis, nasal discharge, airway obstruction and tearing suggest a sinonasal origin (Osguthorpe, 1998). The patients with unilateral proptosis having nasal obstruction require a complete ENT evaluation. The most common neoplasms involving the orbit are of paranasal origin (Khan NH, 2004). In our study nasal obstruction was the predominant symptom noted in 80.9% of our patients; with epistaxis noted in 75% of them with malignancies of nose and paranasal sinuses. Infections, inflammatory diseases and tumours invading the orbit from adjacent areas have rapidly evolving symptoms and pain. Chemosis and injection suggest an inflammatory lesion when combined with proptosis (Osguthorpe, 1998). In our study too patients with benign and inflammatory lesions presented characteristically with epiphora and orbital complaints.

Thus detailed history and clinical evaluation does give valuable hints and help in the diagnosis of patients with unilateral proptosis. Imaging is an important modality in diagnosis of patients with proptosis. Computed tomography (CT) and magnetic resonance imaging (MRI) are very useful tools for the assessment of the lesion, its nature, extent and invasion of adjacent structures. CT is the most commonly used imaging modality because of its wider availability, easy access, lower cost and potential to offer greater anatomic detail. The value of CT scan lies in its ability to demonstrate haematoma, calcification, fracture, bone destruction, and tumours; and to define their orbital and extraorbital extension and their relationship to neighbouring structures (Rauniyar, 2011). In comparison to MRI, CT is particularly effective in delineating calcification and evaluating the pattern of bone invasion (Kawaguchi, 2017). The presence on CT of intrasinous densities as fine punctuate lesions in the central part of the sinus due to metabolic deposits of calcium in the mycelium is noted in fungal rhinosinusitis whereas heterogeneously enhancing mass with areas of high density calcification, bony deformity and sclerosis of the wall of the affected sinus is seen in inverted papilloma. Early CT scan evaluation is a must, as over 33% of patients in the series by Rauniyar R K et al required prompt and adequate medical therapy and another 20% required otolaryngologist's intervention based on CT findings. On CT, though bone destruction with extensive soft tissue invasion is suggestive of malignancies of PNS a few benign conditions like fibrous dysplasia and frontoethmoid mucocele do demonstrate thinning of the bone with areas of bone destruction due to their expansile nature thereby mimicking a malignancy. However a few features on CT like the ground glass appearance in patients with fibrous dysplasia, the remodeling of the neighbouring bone with areas of thinning and erosion in mucoceles are characteristic and help in diagnosis. Mucoceles do not show contrast enhancement centrally but

a thin peripheral enhancement can be seen and is suggestive of encapsulation (Hee Han, 1995). The MRI appearance of paranasal sinus mucoceles is quite variable, depending on the composition of the mucocele (Marrakchi, 2016). In case of inflammatory pseudotumor CT and MRI findings will similarly vary based on the tissues involved, and may show enhancing lesions, lacrimal gland or rectus muscle enlargement, scleral enhancement or inflammation of the eyelids and orbital fat (Sinha, 2005). The diagnosis with imaging can be difficult at times as in case of our patient who had CT and MRI features suggestive of a lymphoproliferative disease but was diagnosed with meningioma on biopsy. Although not pathognomonic, key features which increase the probability of a lesion being a meningioma include intralesional calcifications, skull hyperostosis, local dural enhancement and increased perfusion. It is important to have an awareness of these entities as well as their main imaging findings, as they have a wide range of prognoses and differing management strategies (Lyndon, 2019).

MRI is definitely useful in lesions extending to the orbit and intracranial structures as it helps better soft tissue delineation. Koeller KK et al introduced "space approach" as a means of analysing orbital masses on imaging studies. Determination in which space an orbital mass resides and its other features allows the radiologist to narrow the differential diagnosis and provides essential information for definitive diagnosis and treatment planning (Koeller, 1998). This is useful way for the diagnosis where biopsy is difficult or not possible. The clinical and radiological evaluation though instrumental in making the diagnosis in patients with unilateral proptosis; it is the tissue diagnosis that confirms the same. The use of endoscopes has definitely revolutionized the management of these patients. The nasal corridor can be used to approach the orbit making it possible to obtain biopsies from inaccessible sites with least morbidity. Diagnostic nasal endoscopy and biopsy in our study proved to be the gold standard for diagnosing patients with unilateral proptosis. An endoscope-assisted approach provides three distinct advantages to the surgeon: 1.increased light intensity at the operating site; 2. increased magnification and 3.excellent visualization of poorly accessible sites (Rauniyar R K, 2011). However the histopathological confirmation dictated the treatment in our patients. In case of inflammatory pseudotumor the perivascular lymphocytic infiltration rich in IgG4 positive plasma cells, in fungal rhinosinusitis the invasive broad based nonseptate hyphae with branching at 90 degrees angles suggestive of mucormycosis confirmed diagnosis. The nasal endoscopic approach to the orbit both for biopsy and treatment has definitely improved patient compliance and satisfaction. The treatment is multipronged and decided once the diagnosis and extent of lesion is confirmed. Malignancies of the nose and paranasal sinuses are known to present late especially after the invasion of adjacent structures with local bone destruction.

A high index of suspicion in patients with unilateral proptosis after ruling out local causes is necessary. Our study aims to increase the awareness among clinicians of the varied presentations with different aetiologies likely among patients with unilateral proptosis. Squamous cell carcinoma is the commonest malignancy of sinonasal cavity as was seen in our study too. As the patients presented in the advanced stages; they were counselled of the disease and likely treatment options. As decided in the tumor board 3 of our patients unwilling for surgery received concurrent chemoradiotherapy. The others including our patient with adenoid cystic carcinoma underwent extended maxillectomy with post operative radiotherapy. The appropriate use of obturator after surgery and its refashioning following radiotherapy helped restore feeding early and thereby improve the nutritional status of the patient. We had one case of non Hodgkin's lymphoma characterized by a bulky local disease which did improve with chemotherapy. The benign lesions were all treated with surgery except for inflammatory pseudotumor and Grave's disease wherein the patients improved with medical management itself. All other patients with benign lesions underwent surgery which was a complete excision with biopsy. The endoscopic approach definitely helped reduce morbidity ensuring total clearance. Two of our patients; one with aneurysmal bone cyst and the other one with meningioma underwent combined approach surgery that enabled complete

clearance with good post operative recovery. A multidisciplinary approach with the ophthalmologist, otorhinolaryngologist, neurosurgeon, maxillofacial surgeon, surgical oncologist, pathologist etc definitely benefits management of patients with unilateral proptosis.

## CONCLUSION

Unilateral proptosis is a sign the definitely merits detailed evaluation. "The eyes see only what the mind knows", hence awareness among clinicians of the various presentations likely with differing etiologies is essential. The role of an otorhinolaryngologist is important in these patients especially when they have nasal obstruction, epistaxis and or epiphora. The optimal use of CT and MRI helps reach the diagnosis. The presence of extensive soft tissue involvement and bony destruction should raise the suspicion of a possible malignancy. The nasal endoscope has revolutionized the management of patients with unilateral proptosis by helping both confirmation of diagnosis and enabling treatment with reduced morbidity. Nasal endoscopy with biopsy remains the gold standard for diagnosis. A team effort with technical expertise from required specialties helps plan the optimum treatment with reduced morbidity and mortality.

## REFERENCES

- Hee Han M, Hyun Chang K, Hee Lee C, Gyu Na D, Mo Yeon K, Chung Han M. Cystic expansile masses of the maxilla: Differential diagnosis with CT and MR. *AJNR Am J Neuroradiol*. 1995; 16: 333-338.
- Kawaguchi M, Kato H, Tomita H, Mizuta K, Aoki M, Hara A, Matsuo M. Imaging Characteristics of Malignant Sinonasal Tumors. *J Clin Med*. 2017 Dec; 6(12): 116
- Khan NH, Moin M, Khan MA, Azhar Hameed. Unilateral proptosis: a local experience. *Biomedical*. 2004; 20:114-116.
- Koeller, KK, Smirniotopoulos, JG. Orbital masses. *Semin Ultrasound CT MR* 1998; 19:272-91.
- Kumar DR (1999) A study on etio-pathology of proptosis in Otorhinolaryngology. *Indian J of Otorhinolaryngol Head Neck Surg* 51(4): 1-5.
- Lyndon D, Lansley JA, Evanson J, Krishnan AS. Dural masses: meningiomas and their mimics. *Insights Imaging*. (2019) 10:11.
- Mallajosyula S. Clinical approach to proptosis. In: *Surgical Atlas of Orbital Diseases*. 1st ed. New Delhi: Jaypee Brothers Medical Publishers; 2009.
- Marrakchi J, Nefzaoui S, Chiboub D, et al. Imaging of paranasal sinus mucoceles. *Otolaryngol Open J*. 2016; 2(3): 94-100.
- Merchant RH, Desouza CE, Shah KN, Sakhalkar VS (1993) Proptosis – Management of 22 patients. *Journal of Indian Pediatrics* 30(1) 61- 66.
- Mohan H, Gupta A N. Proptosis - A clinical analysis of 141 cases. *Indian J Ophthalmol* 1968;16(2):91-7.
- Nicole J T, Ann Q T, Eubee B K et al. Etiologies of Proptosis: A review. *Intern Med Rev (Wash D C)*. 2020 Mar; 6(3): 10.18103/imr.v6i3.852.
- Osguthorpe JD, Hochman M. Unilateral Proptosis. In: Gates GA. eds. *Current Therapy in Otolaryngology - Head and Neck Surgery*. Baltimore: Mosby, 1998: 391-395.
- P Keche, A Z Nitnaware, M Mair, P Sakhare, S satpute (2013) A study of tumors giving rise to unilateral proptosis. *Indian J Otolaryngol Head Neck Surgery*. 65(Suppl 1):S6-S13.
- Prabhakaran VC, Selva D. Orbital endoscopic surgery. *Indian J Ophthalmol* 2008; 56(1): 5-8
- Rauniyar R K, Thakur S D , Panda A, Sharma U. Radiological Evaluation of Orbit in cases of Proptosis in Eastern Nepal. *NJR*. 2011; 1(1):8-14.
- Rootman J. *Diseases of the orbit: a multidisciplinary approach*. 2nd ed. Philadelphia: Lippincott Williams & Wilkins; 2003.
- Sinha V, Bhardwaj D, George A, Menon RA. Proptosis through the eye of ENT surgeon. *Indian J Otorayngol Head Neck Surg* 2005;57(3):27-29.
- Susan Dsouza, Pooja Kandula, Gurudutt Kamath, and Manjunath Kamath. Clinical Profile of Unilateral Proptosis in a Tertiary Care Centre. *Journal of Ophthalmology*. 2017, Article ID 8546458, 4 pages.
- Zaidi SH et al. Unilateral proptosis in ENT practices. *J Pak Med Assoc(JPMA)*1991;41(10): 248-250.

\*\*\*\*\*