



ISSN: 2230-9926


Available online at <http://www.journalijdr.com>

IJDR

International Journal of Development Research

Vol. 11, Issue, 03, pp.45020-45022, March, 2021

<https://doi.org/10.37118/ijdr.21243.03.2021>



RESEARCH ARTICLE

OPEN ACCESS

LOWER LIP CANCER – A CASE REPORT

Rosen Tsolov*¹ and Georgi Yordanov²

¹Clinics of Maxillofacial Surgery, UMBAL “St. George” – Plovdiv

²Department of Allergology, Physiotherapy and Clinical radiology, Faculty of Dental Medicine, Medical University of Plovdiv

ARTICLE INFO

Article History:

Received 19th December, 2020

Received in revised form

11th January, 2021

Accepted 20th February, 2021

Published online 15th March, 2021

Key Words:

Lower lip cancer,

A case report.

*Corresponding author: Rosen Tsolov,

ABSTRACT

A case report of a patient with cancer of the lower lip is presented. The reason for the treatment is an entity in the lower lip. It has been dating for several months and has grown significantly lately. Due to the complicated inflammatory process, he was treated in the clinic and after the same subsidence, he was admitted for surgical treatment. Surgery performed *Resectio Partialis Labii Inferioris* and plastics “a modo Bernard”. The case was presented to an oncology council, establishing that the patient was being monitored and he was given recommendations for a hygienic diet. The patient was discharged with improvement.

Copyright © 2021, Anna Cláudia dos Santos Nobre, Manoel Veras de Sousa Neto, Jéssica Morais de Moura e Paula Gonçalves Serafini. This is an open access article distributed under the Creative Commons Attribution License, which permits unrestricted use, distribution, and reproduction in any medium, provided the original work is properly cited.

Citation: Anna Cláudia dos Santos Nobre, Manoel Veras de Sousa Neto, Jéssica Morais de Moura e Paula Gonçalves Serafini, 2021. “Gestão do conhecimento em projetos: revisão terciária em lições aprendidas”, *International Journal of Development Research*, 11, (03), 45020-45022.

INTRODUCTION

Epidemiology

Tendency: Increased incidence of OCC (Oral Cavity Cancer) was founded in Europe in recent years. The frequency in the UK is up to 3%, which would be explained by the higher alcohol consumption (1). The same was reported for African-Americans in USA for the period of 1974-1990. In Japan, there was also an increase incidence of 2.7 / 100 000 in 1975. to 5.4 in 1995, which remained stable as of 2001. In France, on the contrary, the incidence of OCC in men decreased for the period 1980-2000 (1).

Mortality: According to the literature review, the OCC mortality rate has increased over the period 1950-1980 in most European countries (169,265). A significant increase in mortality was observed in men from countries in Eastern Europe (Bulgaria, Czech Republic, Hungary, Poland, Romania and Slovakia) (1). Extremely high levels were observed for Hungary in the mid-1990s, where the mortality rate was 20.2 per 100,000. Young patients in Western Europe have a weak but persistent upward trend in mortality (1,2).

Survival rates: According to the data of leading Bulgarian oncologists, the survival rate from OCC did not increase and half of the patients died in the first two years (1,2,3,4).

OCC mortality is high and, despite advances in cancer treatment, no significant improvement was observed (1,5).

Quality of life: Severe esthetic and functional disorders in eating, swallowing, drinking, speaking are observed in patients with OCC (6). Although these residuals can lead to depression or malnutrition, many patients are coping. Quality of life is extremely important for this group of patients. A very significant problem is the social rehabilitation to prevent the isolation of the patient into society (7,8,9). Very low survival rates have been reported in developing countries, mainly due to late diagnosis. The main cause of death is local recurrence (10).

Case report: In addition to surgical treatment, some of the tasks set include identifying risk factors, social etiology and improving hygiene habits to prevent recurrence and to improve quality of life (9,10,12). Facial asymmetry is observed due to an exophytic formation centrally located on the lower lip with 3x2 cm measurement and several small satellite tumors near the main formation. There is no evidence of lymphadenomegaly in the maxillofacial region. Computed tomography showed a formation in the lower lip. Subthreshold lymph nodes up to 6 mm in size and submandibular bilateral up to 9 mm were visualized. The presence of pronounced degenerative changes in C5 such as the vertebral body is wedge-shaped. ICD code 27.49 Other excision of the mouth.

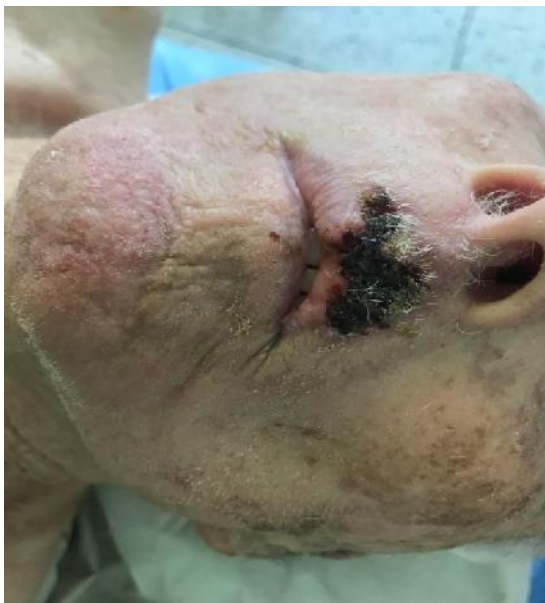

Figure 1. Cancer before treatment

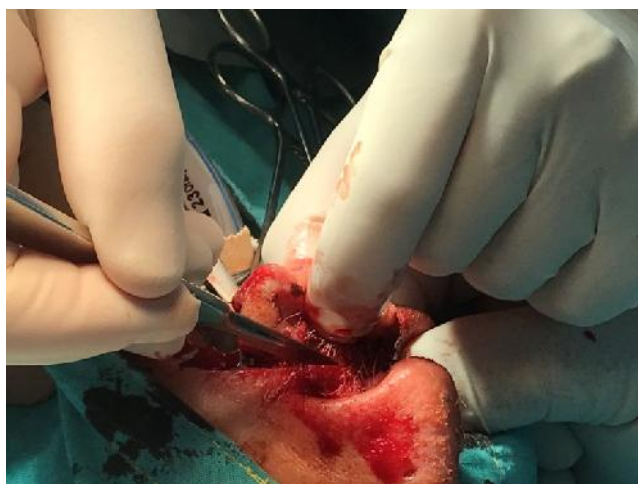

Figure 2. Lower lip resection and formation removal

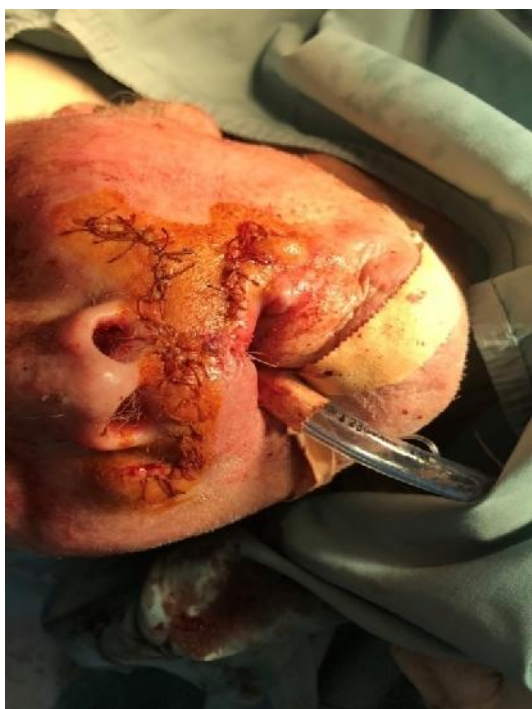

Figure 3. After suturing during intervention

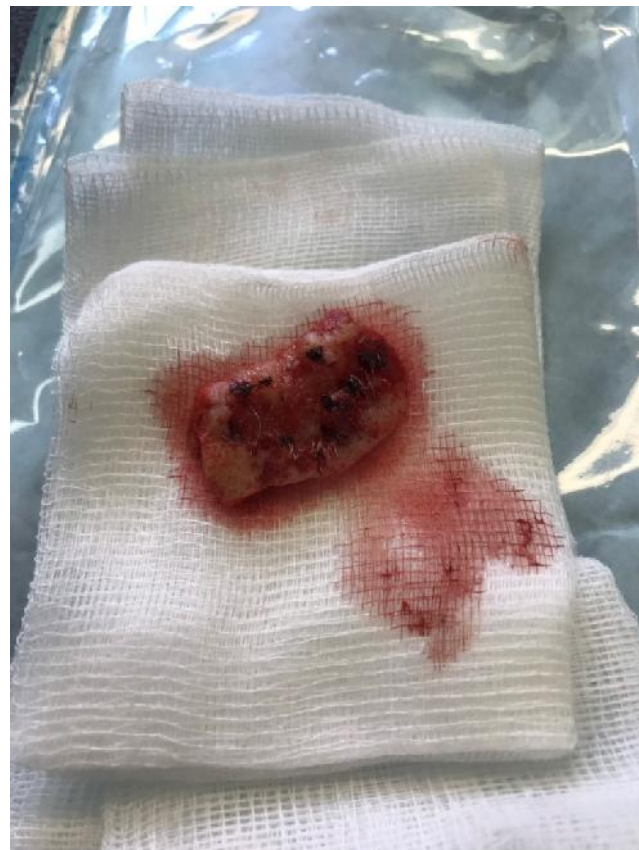

Figure 4. Tumor removal

Therapy: Cefotaxime 1,0 2 1; Fraxiparine 0,4 1 1; Tramalgin 2 1. The scheduled treatment was for 7 days.

DISCUSSION

The case was discussed by an oncology council, whose final conclusion was that the surgical treatment has led to a general improvement of patient's quality of life and he should be a subject to dispensary monitoring. Two controls were appointed within one month - on the 7th and 14th days. Recommendations are given to the patient for the hygiene and nutrition regimen, and to the dentist for the repairment and sanitation of the oral cavity (10,11,12).

Conclusion: The optimal treatment of the patient with ICD 27.49 Other excision of the mouth includes tumor excision, lymph node dissection and reconstruction with plastics "*a modo Bernard*". Recovering of the big lower lip's defect was conducted. This case presents a serious challenge from surgical point of view to guarantee safety and adequate cosmetic and functional improvement of patients with OCC.

REFERENCES

- Bettendorf O, Piffko` J, Ba`nkfalvi A. Prognostic and predictive factors in oral squamous cell cancer: important tools for planning individual therapy? *Oral Oncol* 2004;40:110-9.
- British Dental Association. BDA occasional paper No. 6. Opportunistic oral cancer screening; April 2000.
- Bryne, M, Nielsen K, Koppang, et al. :Reproducibility of two malignancy grading systems with reportedly prognostic value for Oral cancer patients. *J Oral Pathol Med.* 1991 ;20:369-72.
- Daskalova E., Delchev Sl., Peeva Yu., Vladimirova-Kitova L., Kratchanova M., Kratchanov Chr., Denev P. Antiatherogenic and Cardioprotective Effects of Black Chokeberry (*Aronia melanocarpa*) Juice in Aging Rats, *Evid-Based Complement Alternat Med*, 2015, Article ID 717439, <http://dx.doi.org/>

10.1155/2015/717439 ISSN: 1741-427X (Print) ISSN: 1741-4288

Siegelmann-Danieli N, Hanlon A, Ridge JA, et al. Oral tongue cancer in patients less than 45 years old: institutional experience and comparison with older patients. *J Clin Oncol*, 1998; 16(2): 745-753.

Stanimirov Pavel. Prognostic factors in squamous cell carcinoma of the oral cavity (dissertation), Sofia, 2013. Ugrinov R. Maxillofacial and Oral Surgery, Sofia, 2006.

Woolgar JA, Rogers S, West CR, et al. Survival and patterns of recurrence in 200 oral cancer patients treated by radical surgery and neck dissection. *Oral Oncol* 1999; May;35(3):257-65.
